

## Taurodontism; Clinical Considerations

Abu-Hussein Muhamad, Abdulgani Azzaldeen , Abdulgani Mai , Watted Nezar

**Abstract:** Taurodontism is characterized by teeth with enlarged and elongated pulp chambers and apical displacement of the bifurcation or trifurcation of roots. This anomaly occurs either as an isolated, singular trait or in association with syndromes and with some ectodermal anomalies. The aim of this review is to address the etiology, radiographic features and clinical considerations in the treatment of such teeth. It can be seen that taurodontism has until now received insufficient attention from clinicians.

**Keywords:** Taurodontism, taurodont, Hertwig's epithelial root sheath (HERS), bull teeth

### I. Introduction

Taurodontism is one of the anomalies of tooth morphology encountered in the dentition. This anomaly is a developmental disorder of a tooth that shows a lack of constriction at the cement-enamel junction (CEJ) and is characterized by vertically elongated pulp chambers, apical displacement of the pulpal floor and bifurcation or trifurcation of the roots. [1]The origin of the name taurodontism is a combination of the two words "tauros", meaning "bull" in Latin and "odus" which is of Greek origin meaning "tooth" and the initial use of the term, taurodontism, was to describe molar teeth resembling those of ungulates, particularly bulls. [2] Taurodontism is currently defined as tooth morphologic alterations with the absence of the usual constriction at the cemento-enamel junction; apical shift of the pulp chamber floor and furcation area at the expense of the roots and the root canal length. [3]The etiology of taurodontism is still unclear. Some studies suggested that it results from the invagination failure of Hertwig's sheath at the proper horizontal level. [4] Llamas and Jimenez-Planas suggested that the interference in epithelialmesenchymal induction can be considered a possible cause of taurodontism. [5] Other theories that have been postulated include: a primitive pattern, a mutation, a retrograde or specialized character, an X-linked trait, familial or an autosomal dominant trait. [6] while some authors suggest that Taurodontism is due to an ectodermal abnormality. [7]

Numerous theories have been proposed that the condition is related to genetic factors or mutations. [2]Taurodontism seems essentially an isolated anomaly, but has been implicated to occur in association with certain syndromes and genetic disorders that affect tooth morphogenesis, namely: Ectodermal dysplasia; Down's syndrome; McCune-Albright syndrome; Williams's syndrome; Amelogenesis imperfecta; Klinefelter syndrome; Lowe syndrome; Wolf-Hirschhorn syndrome; and Mohr syndrome. [8] Taurodontism was first described in 1908 by Gorjanovic – Kramberger a 70,000 year old pre-Neanderthal fossil, discovered in Kaprina, Croatia. [9]Taurodontism was a frequent finding in early humans and is most common today in Eskimos, possibly as a selective adaptation for cutting hide. The term 'taurodontism' was however first stated by Sir Arthur Keith in 1913. [10]

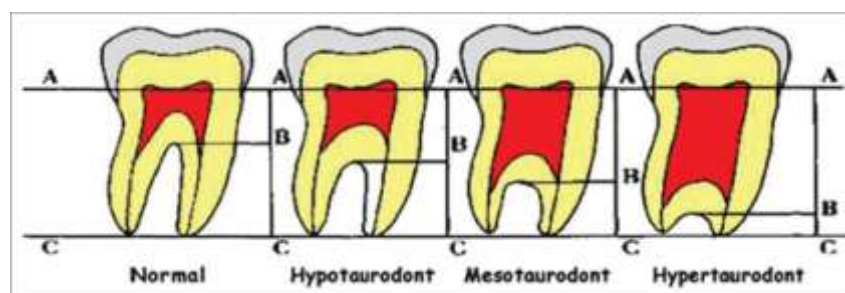


Figure 1 : Witkop's criteria for diagnoses of taurodontism

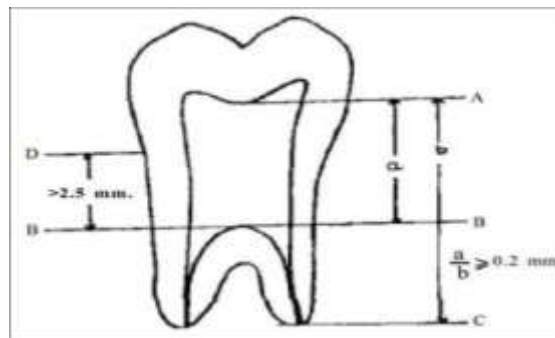
Theories regarding the etiology of taurodontism have been many. It has been suggested that the anomaly represents a primitive pattern, a mutation, a specialized or retrograde character, an atavistic feature, an X-linked trait, familial or an autosomal dominant trait. Although taurodontism has been reported in association with certain syndromes and some genetic defects its true significance is still obscure [2]. Taurodontism appears most frequently as an isolated anomaly, but it has also been associated with several developmental syndromes and anomalies including amelogenesis imperfecta, Down's syndrome, ectodermal dysplasia, Klinefelter syndrome, tricho-dento-osseous syndrome, Mohr syndrome, Wolf-Hirschhorn syndrome and Lowe syndrome

[1]. Taurodontism has also been reported to present with other rare syndromes such as Smith-Magenis syndrome, Williams syndrome, McCune-Albright syndrome and Van der Woude syndrome. [11]

Theories concerning the pathogenesis of taurodontic root formation are also varied: an unusual developmental pattern, a delay in the calcification of pulpal chamber, an odontoblastic deficiency, an alteration in Hertwig's epithelial root sheath. According to some authors, taurodontism is most likely the result of disrupted developmental homeostasis. [2,3,12]

Review of the literature reveals a wide discrepancy in the prevalence of taurodontism in different populations. Its prevalence has been reported to range between 5.67% and 60% of subjects. [12] In a recent study, it has been accounted for 18% of all of the anomalies. [13] The prevalence of taurodontism in children was found in 0.3%. [14] A study on a group of Jordanian dental patients has shown an overall prevalence of 8% for individuals. [15] Ruprecht et al [16] found a prevalence of 11.3% for individuals in Saudi dental patients, whilst the results of Shifman and Channanel [17] were 5.6% in Israeli dental patients, compared with 46.4% in young adult Chinese. [18] These variations in prevalence between different populations may be due to ethnic variations, but may also be influenced by differences in criteria used for interpretation of taurodontism and also the specific teeth examined. [19] Some studies have included premolars, while others believe that premolar teeth may not be affected by taurodontism. It is commonly observed among the Eskimos and Natives of Australia and Central America. [16]

In 1928 Shaw classified this condition as hypotaurodontism, mesotaurodontism and hypertaurodontism based on the relative displacement of the floor of the pulp chamber. [20] This subjective, arbitrary classification led normal teeth to be misdiagnosed as taurodontism. In 1977, Feichfinger and Rossiwall stated that the distance from the bifurcation or trifurcation of the root to the cemento-enamel junction should be greater than the occluso-cervical distance for a taurodontic tooth. [19] Though there are many classification systems to determine the severity of taurodontism, Shifman and Chanannel in 1978 proposed a new classification and is the widely used system till now. [17]

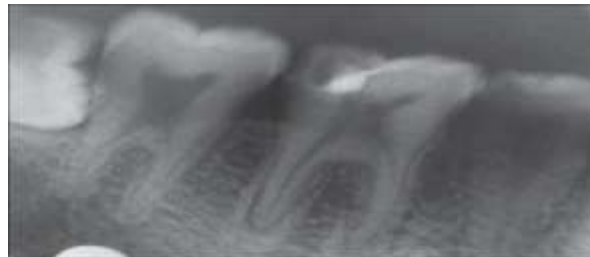


**Figure 2:** Measurements for taurodontic teeth

Cesar in 1971, published the first reported case of taurodontism in the deciduous dentition, where he described it as a definite family trait in Afro-American children. [21] Subsequently, more cases were reported. Goldstein and Gottlieb in 1973 reported cases of taurodontism in families of 14 persons. Familial relationships of taurodontism are evidenced by the fact that 11 of the 14 persons were members of three families. Of the remaining three cases, one is an isolated report, and two appear to have no familial relationship. [10] Bhat et al. in 2004 reported a case of 5-year-old male child having taurodontism in all the deciduous molars. The permanent molars -were normal. The mandibular deciduous molars required pulp therapy, which was performed under local anesthesia in multiple sittings. [6] Rao and Arathi in 2006 reported taurodontism involving all the deciduous and permanent molars (non-syndromic). [22] Bharti et al. in 2009 reported a case of endodontic treatment in a maxillary right first primary molar with taurodontism. In this case, the maxillary right second molar and maxillary left first and second molars were also taurodontic along with the maxillary right first primary molar. [23] Tyagi in 2010 reported a case of a 5-year-old boy with taurodontic lower left second primary molars, which was endodontically treated. [24] Reddy, 2010 reported a unique case of endodontic treatment in a 5-year-old male child with four taurodontic primary molars. [25]

The first report of taurodontism in modern man's dentition was published in 1909 by Pickerill, who used the term "radicular dentinoma" to describe the condition. He described two maxillary first molars exhibiting an overall cuboidal or "bale" shape with normal crowns, and one central quadrilateral-shaped pulp cavity instead of individual root canals. The first permanent molars did not show this trait. [26] Senyurek in 1939 noted taurodontism in the teeth of ancient Egyptians, ancient Icelanders and early American Indians. Following this initial case report, few case of taurodontism was reported in the literature during the next 50 years. Pillai et al. in 2007 reported the presence of taurodontism in premolar in a section of Trinidadian population. Prevalence of taurodontism was assessed by the radiographic study 4.79%, and was found to be

higher in the males as compared to females. Significant differences were also observed between mandibular and maxillary premolars. [27] Joshy et al. in 2011 reported a rare case of a 15-year-old male patient who presented with taurodontism involving all the developed molars in all four quadrants, which was not associated with any other anomaly or syndrome. [28]



**Figure 3:** Hypotaurodontism involving right mandibular first and second molar

## II. The Diagnosis And Classification Of Taurodontism

Clinically, taurodont teeth cannot be diagnosed because the CEJ and roots of a taurodont tooth lie below the alveolar margin, [29] Therefore, the diagnosis of taurodontism is usually made from diagnostic radiographs. [30] Taurodontism can be seen in both the permanent and primary teeth but considered rare in the primary dentition. [15,29] Figure 1

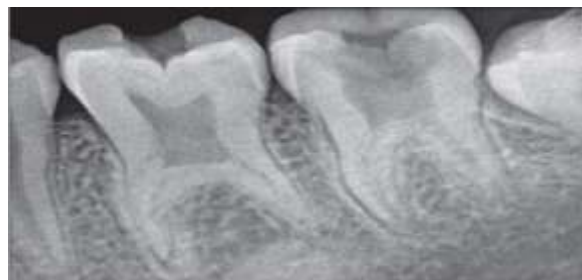Shaw classified taurodontism as hypotaurodontism, mesotaurodontism and hypertaurodontism based on the relative displacement of the floor of the pulp chamber [20]:

**A. Hypotaurodont:** moderate enlargement of the pulp chamber at the expense of the roots.

**B. Mesotaurodont:** pulp is quite large and the roots short but still separate.

**C. Hypertaurodont:** prismatic or cylindrical forms where the pulp chamber nearly reaches the apex and then breaks up into 2 or 4 channels.

This subjective, arbitrary classification commonly led to a misdiagnosis of taurodontism. Although preferred, it is not regarded as an objective analysis. [31]



**Figure 4:** Preoperative radiograph of (mesotaurodontism on mandibular left first molar and hypotaurodontism in second molar

It is important to diagnose taurodontism by means of metric analysis rather than just depending on a visual radiographic assessment which is considered opinionated. [32] Taurodontism may be misdiagnosed in teeth that exhibit attrition and wear-induced secondary dentine deposition in the pulp chambers. Caution should thus be exercised when interpreting taurodontism in severe cases of attrition. [29] Keene suggested a taurodont index that calculates the relation between the height of the pulp chamber and the length of the longest root. He proposed three categories of taurodontism for this index: Normal teeth: index value of 0–24.9%; Hypotaurodont teeth: index value of 25–49.9%; Mesotaurodontism: index value of 50–74.9%; Hypertaurodontism: index value of 75–100%. The disadvantage noted was the use of landmarks that are considered biologically changeable structures, as the pulp chamber undergoes changes with aging and the root length is subjected to change in length, as in external resorption. [33]

Feichtinger and Rossiwall (1977) based the diagnosis of taurodontism on the distance from the bifurcation or trifurcation of the root to the CEJ, which should be longer than the occluso-cervical distance. [34]

A biometric study conducted by Blumberg et al. used five variables to diagnose taurodontism, without specific reference to any classification. The author was of the impression that taurodontism is a continuous anomaly and therefore cannot be placed into strict categories. [3]

**These variables are:**

**Variable 1:** Mesio-distal distance between contact points of the crown.

**Variable 2:** Mesio-distal diameter taken at the level of the cement-enamel junction.

**Variable3:** Perpendicular distance from baseline to highest point on pulp chamber floor.

**Variable 4:** Perpendicular distance from baseline to apex of longest root.

**Variable 5:** Perpendicular distance from baseline to lowest point on pulp chamber roof.

The biometric technique advised by Seow and Lai was employed to establish the diagnosis of taurodontism on panoramic radiographs, by determining the crown-body length (CB) and root length (R) ratio. Based on this ratio, normal teeth (Cynodont) had a CB: R ratio  $<1.10$ , whereas the teeth which had a ratio between 1.10-1.29 were considered hypotaurodontic. Mesotaurodont teeth had a ratio between 1.30 and 2.00, and lastly teeth with ratio  $> 2.0$  were considered hypertaurodontic. [36] Figure 2

Shifman and Chanannel [17] proposed a new classification derived from a taurodontism index (TI), calculated by measuring two variables of molar teeth on radiographs:

**Variable 1:** This is the distance between the lowest point of the roof of the pulp chamber and the highest point in the floor of the pulp chamber.

**Variable 2:** This is the distance between the lowest point of the roof of the pulp chamber and the apex of the longest root.

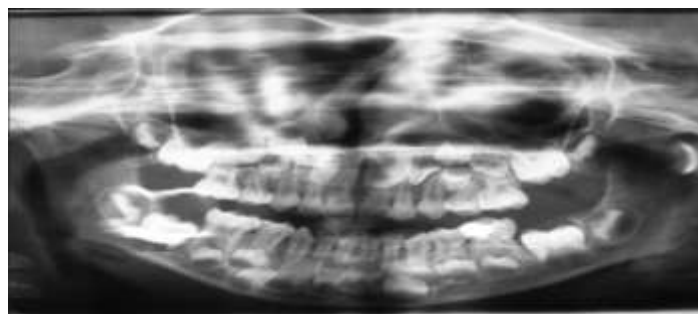
**Variable 3:** The distance between a line connecting both CEJ points, and the highest point of the floor of the pulp chamber.

Taurodont molar teeth were diagnosed when the TI was above 20 and variable 3 measured more than 2.5 mm. By using the taurodontism index TI, the degrees of taurodontism were classified as: hypotaurodontism has a TI from 20 to 30, mesotaurodontism has TI from 30 to 40, while a TI from 40 to 75 presents hypertaurodontism. This is regarded as the most widely used system to date.[17]

In addition to all these methods, Tulensalo et al. examined a simple method of assessing taurodontism using panoramic radiographs by measuring the distance between the baseline (a line connecting the mesial and distal points of the CEJ) and the highest point of the floor of the pulp chamber. [37]A tooth was diagnosed as taurodontic when that distance reached or exceeded 3.5 mm. They concluded that this technique is reliable in epidemiologic investigations for assessing taurodontism in a developing dentition .[38]

In certain metabolic conditions including pseudo-hypoparathyroidism, hypophosphatasia, and hypophosphatemic vitamin D-resistant and dependent rickets, the pulp chamber may be enlarged but the teeth are of relatively normal form. Another differential diagnosis is in the early stages of dentinogenesis imperfecta, where the appearance may resemble the large pulp chambers found in taurodontism. Moreover, the developing molars may appear similar to taurodonts; however, an identification of wide apical foramina and incompletely formed roots helps in the differential diagnosis. Identification of the condition can only be done by radiographic examination as the external morphology of the teeth is within normal configurations. The radiographic examination is the only way to visualize a rectangular configuration of the pulp chamber.[39]

Diagnosis of taurodontism has been based on the subjective radiographic evaluation. The appearance of the taurodont tooth is very characteristic, and the unusual nature of this condition is best visualized on the radiograph. Involved teeth assume a rectangular shape preferably than tapering towards the roots. The pulp chamber is extremely large with a greater apical-occlusal height than normal and lacks the usual constriction at the cervical region of the teeth with exceedingly short roots. The bifurcation or trifurcation may be only a few millimetres (mm) above the apices of the roots.[39]



**Figure 5:** Orthopantomograph showing bilateral taurodontic mandibular first and second primary molars with bilateral primary maxillary first molars with a single root

### **III. Clinical Considerations**

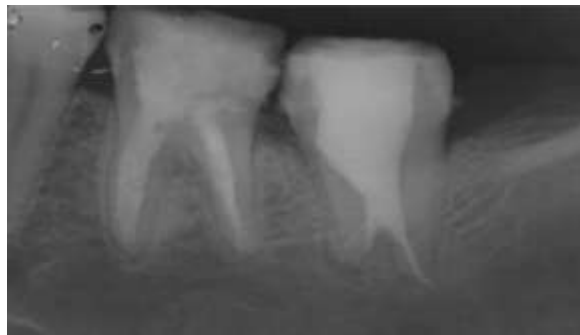The clinical implication of taurodontism has potentially increased risk of pulp exposure because of decay and dental procedures. Taurodontism may complicate orthodontic and/or prosthetic treatment planning. Taurodontism, although not very common has to be emphasized due to its influence on various dental treatments.

### 3.1.Pedodontic consideration

Pulp therapy for taurodonts is a challenging treatment, with increased incidence of haemorrhage during access opening which may be mistaken for perforation. Since the roots are short and pulpal floor is placed apically, care should be taken to prevent perforation. Conventional obturating materials like Zinc oxide eugenol in bulk may take longer time to resorb which may delay the natural exfoliation of the tooth. In such cases combination of calcium hydroxide can act as a wonderful material due to its resorption rate. Endoflas as an obturating material can be used, which is a combination of zinc oxide eugenol, iodoform, calcium hydroxide and barium sulphate. This material has added advantage of faster rate of resorption due to presence of calcium hydroxide and iodoform. [6,25,31] Figure 1

### 3.2.Endodontic considerations:

A taurodont tooth shows wide dissimilarity in the size and shape of the pulp chamber, varying degrees of obliteration and canal configuration, apically positioned canal orifices, and the potential for additional root canal systems. [12] From an Endodontist's view, taurodontism presents a challenge during negotiation, instrumentation and obturation in root canal treatment. Because of the difficulty of the root canal, anatomy and proximity of buccal orifices complete filling of the root canal system in taurodont teeth are challenging. A modified filling technique, which consists of combined lateral compaction in the apical region with vertical compaction of the elongated pulp chamber, has been proposed. [13] Recently, a case report highlights the use of high-end diagnostic imaging modalities such as spiral computerized tomography in making a valid diagnosis of the multiple morphologic abnormalities such as taurodontism, dens invaginations, pyramidal cusps of the premolars, dens evaginatus.[14] The selection of endodontic therapy in these situations will be conservative. Therefore, root canal treatment becomes a difficult. Though taurodontism is of rare occurrence, the clinician should be aware of the complex canal system for its successful endodontic treatment.[2,3] Figure 4 Each taurodont tooth may have extraordinary root canals in terms of shape and number. A complicated root canal treatment has been reported for a mandibular taurodont tooth with five canals, only three of which could be instrumented to the apex . [40]Therefore, careful exploration of the grooves between all orifices, especially with magnification , has been recommended to reveal additional orifices and canals.[41]



**Figure 5:**Endodontic treatment of a mandibular hypertaurodontic second molar

Because the pulp of a taurodont is usually voluminous, in order to ensure complete removal of the necrotic pulp, 2.5% sodium hypochlorite has been suggested initially as an irrigant to digest pulp tissue . [42]Moreover, as adequate instrumentation of the irregular root canal system cannot be anticipated, Wideman & Serene suggested that additional efforts should be made by irrigating the canals with 2.5% sodium hypochlorite in order to dissolve as much necrotic material as possible.[43] Application of final ultrasonic irrigation may ensure that no pulp tissue remains . [42]Because of the complexity of the root canal anatomy and the proximity of the buccal orifices, complete filling of the root canal system in taurodontism is challenging. A modified filling technique has been proposed, which consists of combined lateral compaction in the apical region with vertical compaction of the elongated pulp chamber, using the system B device (EIE/Analytic Technology, San Diego, CA, USA) .[44] Another endodontic challenge related to taurodonts is intentional replantation. The extraction of a taurodont tooth is usually complicated because of a dilated apical third . [41]In contrast, it has also been hypothesized that because of its large body, little surface area of a taurodont tooth is embedded in the alveolus. This feature would make extraction less difficult as long as the roots are not widely divergent ). Finally, it should be noted that in cases of hypertaurodont (where the pulp chamber nearly reaches the apex and then breaks up into two or four channels) vital pulpotomy instead of routine pulpectomy may be considered as the treatment of choice .[17,30] Figure 5,6

### 3.3.Periodontal considerations:

From a periodontal view taurodont teeth may, in specific cases, offer favourable prognosis. Where periodontal pocketing or gingival recession occurs, the chances of furcation involvement are considerably less than those in normal teeth because taurodont teeth have to demonstrate significant periodontal destruction before furcation involvement occurs[42,43,44].

### 3.4.Surgical considerations:

The extraction of a taurodont tooth is usually complicated because of shift in the furcation to apical third. In contrast, it has also been hypothesized that the large body with little surface area of a taurodont tooth is embedded in the alveolus.[2,3] This feature would make extraction less difficult as long as the roots are not widely divergent. It is reported that extraction of such teeth may not be a problem unless the roots are not widely divergent. However, some authors believe that hypertaurodonts may pose some problem during extraction because of apical shift of furcation and also due to difficulty in placement of forceps beaks. This problem can be resolved by proper usage of surgical tooth elevators.[14,32]

### 3.5.Prosthetic considerations:

For the prosthetic treatment of a taurodont tooth, it has been advocated that post placement is avoided for tooth reconstruction. Because less surface area of the tooth is embedded in the alveolus, a taurodont tooth may not have as much strength as a cynodont when used as an abutment for either prosthetic or orthodontic purposes. Since the placement of the stainless steel crown is considered the ultimate extra coronal restoration in pediatric dentistry, the lack of a cervical constriction tends to deprive the tooth of the buttressing effect of excessive loading of the crown.[13]

It is very important for a general dental practitioner to be familiar with taurodontism not only with regards to clinical complications but also its management. Taurodontism also provides a valuable clue in detecting its association with many syndromes and other systemic conditions.

## IV. Conclusion

Taurodontism is a morpho-anatomical developmental anomaly that usually appears in the form of multi-rooted teeth. Taurodontism is a dental rarity. A thorough knowledge of etiology, anatomic and radiographic features and its association with other syndromes of dental rarity should be well understood. From this review, we conclude, it is very important for a pediatric dentist to be well known with taurodontism not only with regards to clinical complications but also its management. Taurodontism also provides a valuable clue in detecting its relation with many syndromes and other systemic conditions

## References

- [1]. Hargreaves, K and Goodis, H., 2002. Seltzer and Bender's Dental Pulp, 3rd ed, Chicago: Quintessence Pub Co
- [2]. Witkop, C., 1971. Manifestation of genetic disease in the human pulp. *Oral Surgery, Oral Medicine and Oral Pathology*, 32: 278–316.
- [3]. Witkop, C., 1976. Clinical aspects of dental anomalies. *International Dental Journal*, 26: 378–90.
- [4]. Reichart, P and Quast, U. 1975. Mandibular infection as a possible aetiological factor in taurodontism. *Journal of Dentistry*, 3: 198–202.
- [5]. Llamas, R., Jimenez-Planas, A., 1993. Taurodontism in premolars. *Oral Surgery, Oral Medicine and Oral Pathology*, 75: 501–5
- [6]. Bhat, S., Sargod, S., Mohammed, SV., 2004. Taurodontism in deciduous molars- A case report. *J Indian Soc Pedod Prev Dent*, 22:193–6
- [7]. Darwazeh, M.G., Hamasha, H., Pillai, K., 1998. Prevalence of taurodontism in Jordanian dental patients. *Dentomaxillofacial Radiology*, 27(3): 163–165.
- [8]. Andersson, E., Axelsson, S., Gjolstad, L., Storhaug, K., 2013. Taurodontism: A minor diagnostic criterion in laurence-moon/bardet-biedl syndromes. *Acta Odontol Scand*, 1–4.
- [9]. Gorjanovic-Kramberger K. Über prismatische Molarwurzeln rezenter und diluvialer Menschen. *Anat Anz*. 1908;32:401–13
- [10]. Goldstein E, Gottlieb MA. Taurodontism: familial tendencies demonstrated in eleven of fourteen case reports. *Oral Surg Oral Med Oral Pathol*. 1973;36:131–4
- [11]. Abu-Hussein M., Watted N., Yehia M., Proff P., Iraqi F. ; Clinical Genetic Basis of Tooth Agenesis, *Journal of Dental and Medical Sciences* 2015 ,14(12),68-77 DOI: 10.9790/0853-141236877
- [12]. Witkop CJ Jr, Keenan KM, Cervenka J, Jaspers MT. Taurodontism: an anomaly of teeth reflecting disruptive developmental homeostasis. *Am J Med Genet Suppl*. 1988;4:85–97.
- [13]. Guttal KS, Naikmasur VG, Bhargava P, Bathi RJ. Frequency of Developmental Dental Anomalies in the Indian Population. *Eur J Dent*. 2010;4:263-9
- [14]. Bäckman B, Wahlin YB. Variations in number and morphology of permanent teeth in 7-year-old Swedish children. *Int J Paediatr Dent*. 2001;11:11-7.
- [15]. Abu-Hussein M, Abdulgani Azzaldeen (2016) Intentional replantation of maxillary second molar; case report and 15-year follow-up. *Journal of Dental and Medical Sciences* 15: 67-73.
- [16]. Ruprecht A, Batniji S, el-Newihi E. The incidence of taurodontism in dental patients. *Oral Surg Oral Med Oral Pathol*. 1987; 63:743-7

- [17]. Shifman A, Chanannel I. Prevalence of taurodontism found in radiographic dental examination of 1,200 young adult Israeli patients. *Community Dent Oral Epidemiol.* 1978;6:200-3.
- [18]. Mac Donald-Jankowski DS, Li TT. Taurodontism in a young adult chinese population. *Dento Maxillo Radiol.* 1993;22:140-4
- [19]. Feichtinger C. Rosiwall B. Taurodontism in human sex chromosome aneuploidy. *Arch Oral Biol.*1977;22:327-9
- [20]. Shaw JC. Taurodont Teeth in South African Races. *J Anat.* 1928;62:476-498.
- [21]. Joshy VR, Jose M, Rajeesh M. Taurodontism of multiple teeth a case report. *Oral Maxillofac Pathol J* 2011;2(1):132-6.
- [22]. Rao A, Arathi R. Taurodontism of deciduous and permanent molars: report of two cases. *J Indian Soc Pedod Prev Dent* 2006;24(1):42-4.
- [23]. Bharti R, Chandra A, Tikku AP, Wadhvani KK. "Taurodontism" an endodontic challenge: A case report *J Oral Sci* 2009;51(3):471-4
- [24]. Tyagi P, Gupta S. Bilateral taurodontism in deciduous molars: A case report. *People's J Sci Res* 2010;3(2):20-3
- [25]. Reddy NV. Endodontic treatment in primary molars with taurodontism – A case report. *Ann Essences Dent* 2010;2(2):52.
- [26]. Senyurek MS. Pulp cavities of molars in primates. *Am J Phys Anthropol* 1939;25:119-31.
- [27]. Mena CA. Taurodontism. *Oral Surg Oral Med Oral Pathol* 1971;32(5):812-23. 28.. Pillai KG, Scipio JE, Nayar K, Louis N. Prevalence of taurodontism in premolars among patients at a tertiary care institution in Trinidad. *West Indian Med J* 2007;56:368-71
- [28]. Terezhalmay, G., Riley, C., Moore, W., 2001. Clinical images in oral medicine and maxillofacial radiology. *Taurodontism. Quintessence International*, 32: 254–5.
- [29]. Neville, B., Damm, D., Allen, C., Bouquot, J., 2002. *Oral & Maxillofacial Pathology*. 5th ed, Philadelphia: W.B. Saunders
- [30]. Jafarzadeh, H., Azarpazhooh, A., Mayhall, J.T., 2008. Taurodontism: A review of the condition and endodontic treatment challenges. *International Endodontic Journal*, 41(5): 375–388
- [31]. Gupta, S.K., and Saxena, P., 2013. Prevalence of taurodontism and its association with various oral conditions in an Indian population. *Oral Health & Preventive Dentistry*, 11(2):155–60
- [32]. Keene, H., 1966. A morphologic and biometric study of taurodontism in a contemporary population. *American Journal of Physical Anthropology*, 25: 208–9.
- [33]. Feichtinger, C., Rossiwall, B., 1977. Taurodontism in human sex chromosome aneuploidy. *Arch Oral Biol*, 22: 327–329.
- [34]. Blumberg, J.E., Hylander, W.L., Goepf, R.A., 1971. Taurodontism: a biometric study. *American Journal of Physical Anthropology*, 34(2): 243–255
- [35]. Seow, W.K and Lai, P.Y., 1989. Association of taurodontism with hypodontia: a controlled study. *Pediatric Dentistry*, 11(3): 214–219.
- [36]. Tulensalo, T., Ranta, R., Kataja, M., 1989. Reliability in estimating taurodontism of permanent molars from orthopantomograms. *Community Dent Oral Epidemiol*, 17: 258–62.
- [37]. Topcuoglu, H.S., Karataş, E., Arslan, H., Koseoglu, M., Evcil, M.S., 2011. The frequency of taurodontism in the Turkish population. *Journal of Clinical and Experimental Dentistry*, 3(4): 284–288.
- [38]. Metgud S, Metgud R, Rani K. Management of a patient with a taurodont, single-rooted molars associated with multiple dental anomalies: a spiral computerized tomography evaluation. *Oral Surg Oral Med Oral Pathol Oral Radiol Endod.* 2009;108:e81-6.
- [39]. Hayashi Y (1994) Endodontic treatment in taurodontism. *Journal of Endodontics* 20, 357–8.
- [40]. Yeh SC, Hsu TY (1999) Endodontic treatment in taurodontism with Klinefelter's syndrome: a case report. *Oral Surgery, Oral Medicine, Oral Pathology, Oral Radiology and Endodontology* 88, 612–5.
- [41]. Prakash R, Vishnu C, Suma B, Velmurugan N, Kandaswamy D (2005) Endodontic management of taurodontic teeth. *Indian Journal of Dental Research* 16, 177–81.
- [42]. Widerman FH, Serene TP (1971) Endodontic therapy involving a taurodontic tooth. *Oral Surgery, Oral Medicine and Oral Pathology* 32, 618–2
- [43]. Tsesis I, Shifman A, Kaufman AY (2003) Taurodontism: an endodontic challenge. Report of a case. *Journal of Endodontics* 29, 353–5.